

# The difficult airway in adult critical care

Gavin G. Lavery, MD, FCARSCI, MB, BCh, BAO (Hons);  
Brian V. McCloskey, MB, BCh, FRCA, FFARCSI, MRCP (UK)

**Introduction:** The difficult airway is a common problem in adult critical care patients. However, the challenge is not just the establishment of a safe airway, but also maintaining that safety over days, weeks, or longer.

**Aims:** This review considers the management of the difficult airway in the adult critical care environment. Central themes are the recognition of the potentially difficult airway and the necessary preparation for (and management of) difficult intubation and extubation. Problems associated with tracheostomy tubes and tube displacement are also discussed.

**Results:** All patients in critical care should initially be viewed as having a potentially difficult airway. They also have less physiological reserve than patients undergoing airway interventions in association with elective surgery. Making the critical care

environment as conducive to difficult airway management as the operating room requires planning and teamwork. Extubation of the difficult airway should always be viewed as a potentially difficult reintubation. Tube displacement or obstruction should be strongly suspected in situations of new-onset difficult ventilation.

**Conclusions:** Critical care physicians are presented with a significant number of difficult airway problems both during the insertion and removal of the airway. Critical care physicians need to be familiar with the difficult airway algorithms and have skill with relevant airway adjuncts. (Crit Care Med 2008; 36:2163–2173)

**KEY WORDS:** airway assessment; airway management; difficult airway; airway obstruction; laryngeal; mask; surgical; intubation technique; tracheal; retrograde; fiberoptic; critical care

**T**he difficult airway has been defined as “the clinical situation in which a conventionally trained anesthetist experiences difficulty with mask ventilation of the upper airway, tracheal intubation, or both” (1). It has been a commonly documented cause of adverse events, including airway injury, hypoxic brain injury, and death in anesthesia (2–8). In the critical care unit, up to 20% of all critical incident reports are airway-related (9–11). For the critical care physician, the challenge is to establish a safe airway, to secure the (long-term) airway, and to manage any potential airway displacement and achieve safe extubation.

## The Difficult Airway: Definition and Prevalence

Airway difficulty can be considered under two distinct headings: a) difficult

mask ventilation (DMV); and b) difficult tracheal intubation. These may be encountered together or in isolation.

DMV can be defined as the inability of an unassisted anesthesiologist a) to maintain oxygen saturation, measured by pulse oximetry, >92%; or b) to prevent or reverse signs of inadequate ventilation during positive-pressure mask ventilation under general anesthesia. In a study of 1,502 patients, DMV was considered present when the anesthetist found that “the difficulty was clinically relevant and could have led to potential problems if mask ventilation had to be maintained for a longer time” (12). There were 75 patients (5%) with DMV but in only 13/75 (17%) had this been predicted. Two subsequent studies reported a DMV rate of approximately 8% (13) and 2% (14).

Difficult tracheal intubation (DTI) is tracheal intubation requiring “multiple intubation attempts in the presence or absence of tracheal pathology” (1). However, there is no universal definition and because the expertise of the intubator, the equipment used, and the number of attempts made may vary, the reported rates of DTI differ. Using direct laryngoscopy only, DTI has been reported in 1.5% to 8.5% of patients—with tracheal intubation impossible in up to 0.5% of the population (7, 15). Failure to intubate the trachea occurs in one in 2,000 in the nonobstetric population and one in 300

in the obstetric population (16). DTI may be the result of difficulty in visualization of the larynx—termed difficult direct laryngoscopy (DDL)—or anatomic abnormality (distortion or narrowing of the larynx or trachea).

Visualization of the larynx is usually described using the Cormack and Lehane grades (17) with grades 3 and 4 indicating DDL. The incidence of DDL is 1.5% to 8% in general surgical patients but higher in patients undergoing cervical spine surgery (20%) (18) or laryngeal surgery (30%) (19). Other grading systems for visualization of the larynx exist, including a modified Cormack and Lehane (20) and the Percentage of Glottic Opening scale (21).

The need for equipment other than a direct laryngoscope may also help define DTI, although devices such as the gum elastic bougie (introducer) may or may not be viewed as part of standard technique. Many of these issues are addressed in the intubation difficulty scale (IDS) (22), which uses seven variables to calculate a score. An IDS score of 5 has been used to define DTI and, in a large study, occurred in 8% of patients (23).

## The Difficult Airway: Prediction

The conditions associated with airway difficulty are numerous (24, 25) (Table 1). Past airway difficulty is a significant pre-

From School of Health & Life Sciences (GGL), University of Ulster, Belfast, and Anaesthesia & Intensive Care Medicine, Regional Intensive Care Unit, Royal Hospitals, Belfast Health & Social Care Trust, Belfast, UK; and Anaesthesia & Intensive Care Medicine (BVM), Regional Intensive Care Unit, Royal Hospitals, Belfast Health & Social Care Trust, Belfast, UK.

The authors have not disclosed any potential conflicts of interest.

For information regarding this article, E-mail: gavin.lavery@belfasttrust.hscni.net

Copyright © 2008 by the Society of Critical Care Medicine and Lippincott Williams & Wilkins

DOI: 10.1097/CCM.0b013e31817d7ae1

**Table 1.** Conditions associated with difficult airway (24, 25). [Also see <http://www.erlanger.org/craniofacial> and <http://www.faces-cranio.org>]

- Abnormal facial anatomy/development
  - Small mouth and/or large tongue
  - Dental abnormality
  - Prognathia
  - Obesity
  - Advanced pregnancy
  - Acromegaly
  - Congenital syndrome, e.g. Treacher Collins syndrome
- Inability to open mouth
  - Masseter muscle spasm (dental abscess)
  - Temporomandibular joint dysfunction
  - Facial burns
  - Post-radiotherapy fibrosis
  - Scleroderma
- Cervical immobility/abnormality
  - Short neck/obesity
  - Poor cervical mobility, e.g. Ankylosis spondylitis
  - Previous cervical spine surgery
  - Presence of cervical collar
  - Post-radiotherapy fibrosis
- Pharyngeal and laryngeal abnormality
  - High or anterior larynx
  - Deep vallecula (inability to reach base of epiglottis with blade of scope)
  - Anatomical abnormality of epiglottis or hypopharynx, e.g. tumor
  - Subglottis stenosis

dicator of future problems unless a temporary factor, for example, airway swelling, pharyngeal abscess, was responsible. The finding of limited mouth opening, dysphonia, dysphagia, dyspnea, or stridor suggests pharyngeal-, neck- or mediastinal-related pathology, which is often relevant. It has been stated, however, that accurate prediction of airway difficulty is a myth but that the exercise is useful in focusing our attention on potential airway strategy (26).

Five criteria have been identified using multivariate analysis as independent risk factors for DMV (15) (age >55 yrs, body mass index >26 kg/m<sup>2</sup>, presence of beard, lack of teeth, history of snoring). The presence of two factors indicated high likelihood of DMV (sensitivity, 0.72; specificity, 0.73). Limited mandibular protrusion has been associated with both DMV and DTI (14).

A clinical assessment developed to attempt prediction of DTI is the Mallampati test (27). Originally this graded the patient (grades 1–3) based on the structures visible in the oropharynx under set conditions with maximal mouth opening; a fourth grade was added subsequently (16). Although grades 3 and 4 suggest difficult tracheal intubation, grading is subject to significant interobserver vari-

ation. In a series of 1,956 adult elective surgical patients receiving general anesthesia, Cattano et al. (28) showed that, although the Mallampati scale had a good correlation (.90) with the Cormack and Lehane classification, it lacked the sensitivity to be predictive for difficult intubation and stated the score alone was “insufficient for predicting difficult tracheal intubation.” Other relevant anatomic indices (interincisor gap, thyromental distance, mentohyoid distance, sternomental distance, and neck mobility) were found to be of even less predictive value. The accuracy of sternomental distance as a predictive index has been described as “approaching worthlessness” (29). The reported association of DTI and male gender, increased age, decreased neck mobility, history of obstructive sleep apnea, temporomandibular joint pathology, Mallampati 3 or 4, and abnormal upper teeth (30–34) are of little predictive value.

Disease processes such as neoplasm of the pharynx or larynx (19) may be associated with DTI. The presence of a thyroid mass has been reported to be associated with DTI (35–37) and would certainly make an emergency cricothyroidotomy difficult or impossible in the event of failure to ventilate. However, three studies (38–40) suggest only marginally increased difficulty in intubating patients presenting with thyroid disease, the most recent finding being a difficult intubation rate of 11%. Acromegaly (41), the presence of a large or poorly compliant tongue (42), or decreased compliance of the submental tissues may be associated with DTI.

The poor predictive ability of individual factors, tests, or measurements prompted evaluation of combinations and the development of scores and indices. Wilson et al. developed a score based on body weight, head and neck movement, jaw movement, and the presence or absence of mandibular recession and protruding teeth (43). However, it had a false-positive rate of 12% and combining it with the Mallampati score appeared to increase false-positives (44). More recently, this combination has shown a sensitivity of 100%, specificity of 96%, and positive predictive value of 65% in a study of 372 obstetric patients (45). The combination of Mallampati 3 or 4, interincisor distance of 4 cm or less, and thyromental distance of 6.5 cm or less has been shown to have 85% sensitivity and 95% specificity for DTI (46). Other scores include the Arne (47) and El-Ganzouri

risk indices (34). The former was devised from 1,200 consecutive general/ear, nose and throat surgical patients and prospectively evaluated in a further 1,090. Although the sensitivity and specificity are above 90% for most patient groups, the predictive value is still limited.

The evidence regarding obesity as a risk factor for airway difficulty is hard to interpret. Increased body mass index (BMI) is a risk factor for DMV (12) and the Wilson score is influenced unfavorably by increased body weight (43). Older studies of “normal” patients suggested obesity was a risk factor for difficult intubation (5, 48). In a more recent study (49), an IDS >5 was found in 15.5% of patients with a BMI >35 kg/m<sup>2</sup> but only 2.2% of patients with a BMI <30 kg/m<sup>2</sup>. However, when 200 morbidly obese patients were compared with 1,272 nonobese control subjects, increased BMI had no influence on intubation difficulty (31). Brodsky et al. (50), in a series of 100 patients with a median weight of 137 kg and BMI >40 kg/m<sup>2</sup>, found that degree of obesity, BMI, and a history of obstructive sleep apnea were not associated with difficult intubation, but increased neck circumference (at the level of the superior border of the cricothyroid cartilage) was a predictor of potential intubation problems. This is in conflict with Komatsu et al. who found that the thickness of pretracheal soft tissue, at the level of the glottis, as measured by ultrasound, was not a predictor of difficult intubation (51). Because most patient populations show a low prevalence of difficult airway and tests have low predictive power, a preplanned strategy is central to managing airway problems when they occur (15, 52).

### The Airway Practitioner and the Clinical Setting

Inability to establish a definitive airway may be the result of inexperience and/or lack of skill on the part of the practitioner (53–58). Lack of skilled assistance is also an important factor in scenarios in which airway problems are reported (59–62). Airway and ventilatory procedures in the prehospital setting and “in-hospital but outside the operating room (OR)” show a higher frequency of adverse events and a higher risk of mortality than similar events in an OR (63–67). Inexperience, poor assistance, and an unfavorable environment may combine

leading to a failure to optimize conditions. Common errors include poor patient positioning; failure to ensure appropriate assistance; faulty light source in laryngoscope/no alternative scope; failure to use a longer blade in appropriate patients; use of inappropriate tracheal tube (size or shape); and a lack of immediate availability of airway adjuncts.

In the critical care unit, all invasive airway maneuvers are potentially difficult (68). Positioning is more difficult on an intensive care unit bed than an OR table. The airway may be edematous as a result of the presence of an endotracheal tube (ETT) or previous airway instrumentation. Neck immobility or the need to avoid movement in a potentially unstable cervical spine will add to the difficulty (69–71). Halo fixation (without elective tracheostomy) carries a high risk (14%) for emergent/semi-emergent intubation and airway-associated mortality (72). Poor gas exchange in intensive care unit patients may reduce the effectiveness of preoxygenation thus increasing the risk of significant hypoxia if there is delay in securing the airway (73). Cardiovascular instability may produce hypotension, hypoperfusion, and misleading (or absent) oximetry readings, a further confounding factor for the attending staff.

### Managing the Difficult Airway

This has been considered under three headings: a) the anticipated difficult airway; b) the unanticipated difficult airway; and c) the difficult airway resulting in a “cannot intubate and cannot ventilate” situation (74).

Those involved in airway management must have: a) expertise in recognition/assessment of the potentially difficult airway; b) the ability to formulate a plan (and alternatives) for airway management (1, 2, 75–77); c) familiarity with schemes that outline a sequence of actions designed to maintain oxygenation, ventilation, and patient safety. (The American Society of Anesthesiologists difficult airway algorithm [1] is the most widely promulgated example. Another is the airway plans from the Difficult Airway Society [75]); and d) the skills and experience to use airway adjuncts, particularly those relevant to the unanticipated difficult airway.

### The Anticipated Difficult Airway

This is the “least lethal” of the three scenarios with time to consider strategy,

optimize the situation, and obtain appropriate adjuncts and personnel. The key questions are, “Should the patient be kept awake or anesthetized for intubation” and “Which intubation technique should be used?”

### Awake Intubation

Awake intubation is more time-consuming, needs experienced personnel, is less pleasant (than intubation under anesthesia), and may have to be abandoned as a result of the patient’s inability or unwillingness to cooperate. However, because spontaneous breathing and pharyngeal/laryngeal muscle tone is maintained, it is significantly safer.

### Fiberoptic Intubation

Although comparative research in this field is rare, most experts agree that awake fiberoptic intubation is the technique of choice with an informed, prepared patient and a trained operator with appropriate equipment. The technique ensures that spontaneous respiration and upper airway tone can be maintained and has been extensively described by others (78–83).

Adequate psychological preparation is essential. Numerous sedation agents have been evaluated, including benzodiazepines, opioids such as alfentanil or remifentanil, and intravenous anesthetic agents such as (low-dose) propofol infusion (84). Supplemental oxygen should be provided, usually through the contralateral nostril. Care must be taken not to overdose the patient and to maintain spontaneous respiration throughout.

Topical anesthetic agents include lignocaine ± phenylephrine or cocaine. Cocaine has the advantage of producing vasoconstriction but has been associated with myocardial ischemia. Nebulized lignocaine can be used but may result in high blood lignocaine levels, coughing, and bronchospasm. Anesthesia of the vocal cords and upper trachea is usually provided by a “spray as you go” technique using 2% lignocaine. Another potential technique is superior laryngeal and recurrent laryngeal nerve blockade (85).

Fiberoptic intubation is usually more straightforward through the nasal (rather than oral) route. The operator may stand either behind the patient’s head or to the side, facing the patient. The vocal cords should be visualized and then lignocaine sprayed through the cords. The scope

may then be advanced to the midtracheal level and the carina visualized. The ETT may then be placed carefully through the nasal cavity and into the trachea. Occasionally the passage of the ETT may be impeded by the vocal cords. Withdrawing the ETT, rotating 90° anti-clockwise, and readvancing usually resolves this problem. The presence of end-tidal carbon dioxide confirms tracheal position. The ETT should be positioned approximately 3 cm above the carina.

### Retrograde Intubation

Under local anesthesia, a cannula is inserted through the cricothyroid membrane into the trachea (Fig. 1.1) and a guidewire is passed through the needle upward through the vocal cords into the pharynx or mouth (86, 87). If necessary, forceps may be used to retrieve the guidewire and bring it out through the mouth (Fig. 1.2). The wire is then used to guide an ETT (railroaded over an endotracheal exchange catheter) through the vocal cords (Fig. 1.3) before the withdrawal of the wire through the cannula and further advancement of the ETT into the trachea (Fig. 1.4). A common variation to this technique is to use the wire to guide a fiberoptic scope through the vocal cords, thus facilitating a fiberoptically guided intubation (86–88). With this technique, the wire must be longer than the fiberoptic scope plus the airway down to the glottis. A long angiography guidewire is appropriate, whereas a central venous catheter guidewire is not.

### Intubation Under Anesthesia

Despite the safety advantage of awake intubation in these patients, anesthesia before attempted orotracheal intubation may be viewed as more appropriate. This strategy should only be used by those skilled and experienced in airway management. Preparation of the patient, equipment, and staff is paramount (Table 2). Adjuncts (see subsequently) should be available, either to improve the chances of intubation or to provide a safe alternative airway if intubation cannot be achieved. The central principle is the induction of deep anesthesia, sufficient to allow direct laryngoscopy and tracheal intubation without the use of a muscle relaxant, with maintenance of spontaneous respiration. This involves an inhalational induction using a volatile agent (for example, sevoflurane) or the slow adminis-

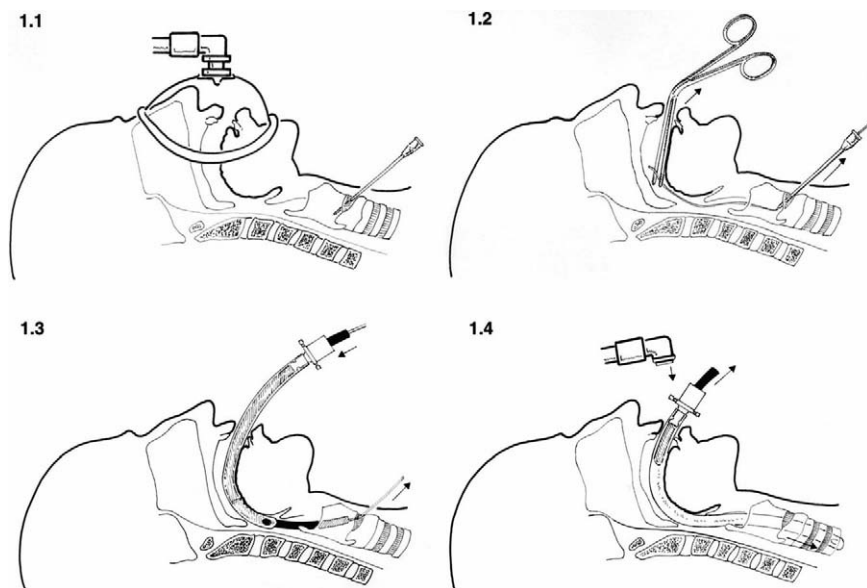


Figure 1. The technique of retrograde intubation (see text).

Table 2. Requirements for anticipated difficult intubation following general anaesthesia

- Fasting patient with empty stomach
- Antacid therapy
- Optimal patient positioning
- Full vital sign monitoring
- Availability of
  - Gum elastic bougies
  - Tracheal tubes of various sizes
  - Tube introducers
  - Several sizes and types of laryngoscope blades
  - Lighted stylet/light wand
  - Laryngeal masks (various sizes) or combitube
  - Cricothyroidotomy or mini-tracheostomy kit
- Pre-oxygenation of the patient
- Technique that maintains spontaneous respiration until tracheal intubation/ventilation is confirmed
- Use of bimanual laryngoscopy or guided BURP if required (see text)
- Use of above adjuncts

BURP, backward, upward, and rightward pressure.

tration of an intravenous induction agent (for example, propofol) followed by an inhalational technique. The latter, although quicker, may cause apnea and (if manual ventilation cannot be achieved) a life-threatening situation.

Orotracheal intubation without neuromuscular blocking drugs may be facilitated by the use of lignocaine spray to the mucosa of the larynx and pharynx before intubation. Intubating conditions may not be as favorable as under the influence of neuromuscular block and, if

passage of the tube into the trachea is not achieved relatively quickly, the patient (now breathing room air) will become less deeply anesthetized, making intubating conditions even more difficult. Kabrhel and colleagues (89) have recently published a detailed description of the procedure of orotracheal intubation using direct laryngoscopy.

### Unanticipated Airway Difficulty

The unanticipated difficult airway allows only a short period to solve the problem if significant hypoxemia, hypercarbia, and hemodynamic instability are to be avoided. The patient is usually anesthetized, may be apneic, and may have had muscle relaxants and several unsuccessful attempts at intubation. If appropriate equipment, assistance, and experience are not immediately at hand, there is little time to obtain these. Oxygenation must be maintained and hypercapnia avoided.

If the practitioner is inexperienced, the patient has had no (or a relatively short-acting) muscle relaxant and manual ventilation is not a problem, it may be appropriate to let the patient recover consciousness. An awake intubation can then be planned either after a short period of recovery or on another occasion. With an experienced practitioner, it may be possible to continue using techniques to improve the chances of visualizing and intubating the larynx. The adjuncts described subsequently may be useful in this situation, but also for the anesthe-

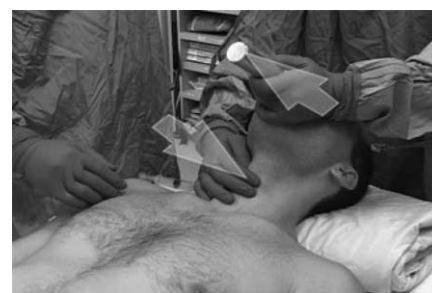

Figure 2. Bimanual laryngoscopy. Arrows demonstrate use of one hand to control the laryngoscope and the other to apply cricoid pressure or a backward, upward, and rightward pressure (BURP)-type maneuver. Reproduced with permission from [www.airwaycam.com/bimanual.aspx](http://www.airwaycam.com/bimanual.aspx). Accessed May 29, 2008.

tized patient with an anticipated difficult airway.

### Bimanual Laryngoscopy

Backward pressure on the cricoid cartilage, or the BURP maneuver (backward, upward, and rightward pressure), applied by an assistant may improve the view of the larynx at direct laryngoscopy (90, 91). The benefit of BURP may be enhanced further by combining it with mandibular advancement (often helpful in fiberoptic intubation) (92). However, cricoid pressure and BURP, when performed by a “blinded” assistant, has also been shown to impair laryngeal visualization on approximately 30% of occasions (93–95). External laryngeal manipulation (also termed bimanual laryngoscopy) involves a cricoid pressure- or BURP-type maneuver performed initially by the laryngoscopist (Fig. 2) and then maintained by an assistant. It has been shown to improve the view at direct laryngoscopy (91, 96). Direct comparison has shown that external laryngeal manipulation (bimanual laryngoscopy) is superior to BURP in improving laryngeal visualization, whereas cricoid pressure is the least effective technique (93).

### Stylet (‘Introducer’) and Gum Elastic Bougie

The stylet is a smooth, malleable metal or plastic rod that is placed inside an ETT to adjust the curvature, typically into a J or “hockey stick” shape to allow the tip of the ETT to be directed through a poorly visualized or unseen glottis (97). The stylet must not project beyond the end of the ETT to avoid potential airway injury. In contrast, the gum elastic bougie is a blunt-ended, malleable rod that

may be passed through the poorly or non-visualized larynx by putting a J-shaped bend at the tip and passing it “blindly” in the midline upward beyond the base of the epiglottis. The ETT can then be “railroaded” over the bougie, which is then withdrawn. For many, it is the first choice adjunct in the difficult intubation situation (91, 98). There has been much debate regarding the relative merits of the bougie (used widely in the United Kingdom) and stylet (more popular in North America) (99, 100).

### Choice of Laryngoscope Blade

There are over 50 types of curved and straight laryngoscope blades of varying sizes. Using specific blades in certain circumstances is felt to be very advantageous by some (101–103) but not all authorities (104). In patients with a large lower jaw or “deep pharynx,” the view at laryngoscopy may be improved significantly by using a size 4 Mackintosh blade (rather than the more common size 3) to ensure the tip of the blade reaches the base of the vallecula to facilitate optimal elevation of the epiglottis. Other blades, for example, McCoy (a curved Mackintosh-type blade with a laryngoscopist-controlled hinged portion just proximal to the tip), may be advantageous in specific situations (105, 106). Figure 3 shows a selection of curved and straight laryngoscope blades.

### Lighted Stylet

The lighted stylet (light wand) is a malleable fiberoptic light source on which an ETT can be mounted and subsequently railroaded into the trachea when the light source has passed beyond the glottis (107). It facilitates blind tracheal intubation by distinguishing the tracheal lumen from the (more posterior) esophagus as a result of the greater intensity of light visible through anterior soft tissues of the neck as the light source passes beyond the vocal cords (108). During routine general anesthesia, intubation time and failure rate with light wand-assisted intubation is similar to direct laryngoscopy (109) and in a large North American survey, it was the most popular alternative airway device in the difficult intubation scenario (110). It may be used in conjunction with the laryngeal mask airway or as part of a combined technique with a fiberoptic scope (111, 112). A potential disadvantage is the need

for low ambient light, which may not be desirable (or easily achieved) in a critical care setting. Light wand devices may be contraindicated in patients with known abnormal upper airway anatomy and those in whom detectable transillumination is unlikely to be adequately achieved (107).

### Fiberoptic Intubation

The fiberoptic scope (see previously) can be used in the unanticipated difficult airway but only if it is readily available and the operator is skilled (7, 78, 79). In this scenario, the oral route may be advantageous in terms of speed. Modified oral airways that also act as a bite guard may be helpful (113). When the patient has been anesthetized, loss of muscle tone allows the epiglottis and tongue to fall back against the posterior pharyngeal wall. The jaw may need to be lifted forward to gain optimal visualization of the vocal cords (79, 92). Intubation can also be accomplished with a video laryngoscope (114) in which the view from the end of the laryngoscope is transmitted fiberoptically to a monitor screen. The screen displays the larynx and the ETT as the latter is advanced to the correct position.

### Supraglottic Airway Devices

*Laryngeal Mask Airway.* After the introduction of the laryngeal mask airway (LMA) in 1988, supraglottic airway devices rapidly found a significant role in the management of the difficult airway. They are extensively reviewed by Cook (115). The classic LMA (cLMA) is a small latex mask mounted on a hollow plastic tube (18, 116–121). It is placed “blindly” in the lower pharynx overlying the glottis. The inflatable cuff on the mask helps wedge the mask in the hypopharynx so that it sits obliquely over the laryngeal inlet. Although the LMA produces a seal that will allow ventilation with gentle positive pressure, it does not definitively protect the airway from aspiration. Compared with an ETT, an LMA can be appropriately placed more rapidly and more successfully by operators with limited advanced airway skills (122, 123). The use of the LMA has been extensively studied in cardiac arrest situations and found to be superior to bag mask ventilation. The often quoted risk of pulmonary aspiration is probably overestimated; some reported aspiration probably occurs before insertion of the LMA (124). Concerns of inadequate ventilation (leakage of gas) or




Figure 3. Lateral view of straight and curved laryngoscope blades. A–C, Mackintosh Blades (sizes 4, 3, and 2). D, Miller blade; E, McCoy blade (tip in “elevated” position).

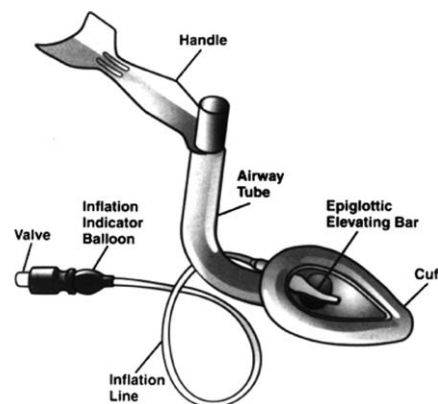


Figure 4. The intubating laryngeal mask airway. Reproduced with permission from Brain AJ, Verghese C: Laryngeal Mask Airway (LMA)-Fastrach Instruction Manual. San Diego, LMA North America, 1998.

gastric inflation, however, remain. Ventilation is possible through the LMA if inflation pressures are kept relatively low. Increasing peak airway pressure from 15 cm H<sub>2</sub>O to 30 cm H<sub>2</sub>O may increase the proportion of gas leakage from 13% to 27% and, more importantly, increase the proportion entering the esophagus from 2% to 35% (125).

Modifications of the cLMA include the intubating LMA (ILMA), the Proseal LMA (Intavent Orthofix, Maidenhead, Berkshire, UK), and various disposable LMAs. The ILMA (Fig. 4) has a more rigid, wider tube with a handle for insertion (126–129). A modified tracheal tube with a low profile cuff can be passed through the ILMA into the trachea (130) either blindly or with the aid of a fiberoptic scope. A “bar” overlying the lower aperture lifts the epiglottis forward revealing the laryngeal inlet and facilitating intubation. The ILMA may be suitable in the management of trauma patients in situations of limited

access or when cervical spine injury is suspected (131).

The Proseal LMA was introduced in 2002 as a device to ensure better airway protection and more successful ventilation. It differs from the cLMA in having a larger deeper mask and a posterior cuff. A drain tube reduces the possibility of leaked gases entering the esophagus and acts as a vent if regurgitation occurs (132).

### Combitube (Esophageal-Tracheal Double-Lumen Airway)

The Combitube (Tyco-Kendall-Sheridan, Manstield, MA) is a combined esophageal obturator and tracheal tube and is usually inserted blindly (15, 24, 97, 115, 133–135). Whether the “tracheal” lumen is placed in the trachea or esophagus, the Combitube (Fig. 5) will allow ventilation of the lungs and give partial protection against aspiration. In many situations, the Combitube is a (less widely used) alternative to the LMA, including the “cannot intubate–cannot ventilate” situation. Disadvantages include the inability to suction the trachea when placed in the esophagus (the most common position). Insertion may also cause trauma and is contraindicated in patients with known esophageal pathology, intact laryngeal reflexes, or in those who have ingested caustic substances.

### Failure to Intubate and Failure to Ventilate

This is an absolute emergency and a grave threat to life. To ensure all involved perform at their best, it is important to

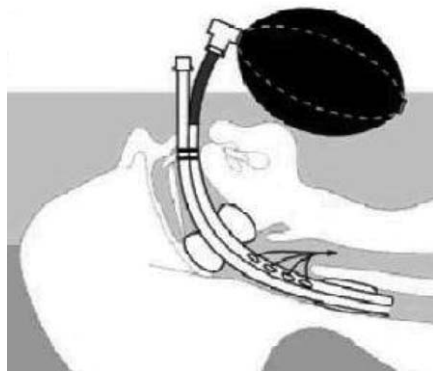


Figure 5. Combitube (allowing pulmonary ventilation if tube is inserted into the esophagus). Reproduced with permission from Daniele Focosi's Molecular Medicine Web site ([http://focosi.immunesisg.org/invivo\\_surgical.html](http://focosi.immunesisg.org/invivo_surgical.html)). Accessed May 29, 2008.

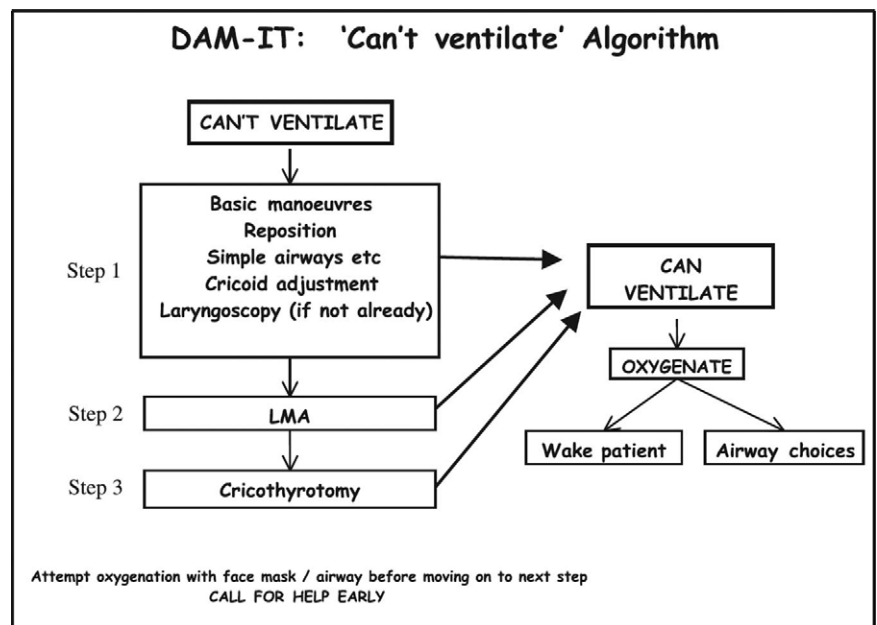
remain calm and follow an appropriate algorithm. The options are to find a satisfactory method of ventilation without intubation (“noninvasive”) or to perform a cricothyroidotomy or (potentially) tracheostomy (1, 2, 75). Reduced to its simplest, the options are a) check the basics to see if intubating conditions can be improved; b) use of a supraglottic airway; or c) perform a cricothyroidotomy (Fig. 6), which may be more easily remembered using the phrase “Fiddle, Larry, Stick” (136). Once ventilation and oxygenation is achieved, the options are wake up or continue using further options undertaken in a controlled manner with additional help.

### Confirming Tube Positioning in the Trachea

In managing the difficult airway, one of the most disastrous possibilities is the

failure to recognize misplacement of the ETT, usually in the esophagus. This is not a life-threatening situation unless it is unrecognized (137). Thus, confirmation of ETT placement in the trachea is essential. Visualizing the tube passing through the glottis into the trachea is the definitive method to assess correct positioning. This may not always be possible as a result of poor visualization and (potentially) the operator's reluctance to accept that the tube is not in the trachea. There are several clinical observations that support the presence of the ETT in the trachea.

Chest wall movements on manual ventilation are usual but may be absent in patients with chronic obstructive pulmonary disease, obesity, or decreased compliance, for example, severe bronchospasm. Although the presence of condensed water vapor in the ETT suggests that expired gas is from the lungs, this



Failed intubation alone is not a crisis if the lungs can still be ventilated, whereas failed ventilation may well be. The priority is to oxygenate the lungs.

If ventilation cannot be achieved, rapidly follow the steps in the Figure:

- i) Step 1: basic manoeuvres
- ii) Step 2: LMA (may have to release cricoid pressure to insert)
- iii) Step 3: cricothyrotomy

Once ventilation is achieved, there should be time to consider the options: either wake the patient or continue using one of a variety of airway choices:

- i) Laryngeal mask
- ii) Intubating laryngeal mask + tube
- iii) Fiberoptic intubation through mouth / nose / laryngeal mask
- iv) Other device

In most cases, wake the patient unless his/her life is in imminent danger, and seek more senior help.

If a tracheal tube is placed, its position should always be checked. Extubation (when, where and how) should also be considered.

Figure 6. Simple flow chart for the “cannot intubate–cannot ventilate.” Reproduced with permission from Mulcahy AJ, Yentis SM: Management of the Unexpected Difficult Airway. Anesthesia. Oxford, Wiley-Blackwell Publishing Ltd, 2005. LMA, laryngeal mask airway.

may occur with esophageal intubation. The absence of water vapor is more strongly suggestive of esophageal intubation. Auscultation of breath sounds (in both axillae) supports correct tube positioning but is not absolutely confirmatory (138).

The use of capnography to detect end-tidal carbon dioxide is the most reliable method of confirming ETT placement and is increasingly available in critical care (139). False-positive results may occur initially when exhaled gases enter the esophagus during mask ventilation (140) or when the patient is generating carbon dioxide in the gastrointestinal tract, for example, recent ingestion of carbonated beverages or bicarbonate-based antacids (141). A false-negative (ETT in the trachea but no CO<sub>2</sub> detected) may occur when pulmonary blood flow is minimal, for example, during cardiac arrest with poor cardiopulmonary resuscitation (142).

Visualizing the trachea or carina through a fiberoptic bronchoscope, which should be readily available in critical care, will also confirm correct placement of the ETT. Note that after emergency intubation and clinical confirmation of the ETT in the trachea, 15% of ETTs may still be inappropriately close to the carina (143).

## Surgical Airway

The indication for a surgical airway is inability to intubate the trachea in a patient who requires it and the techniques available are cricothyroidotomy or tracheostomy (24). Conventional wisdom states that tracheostomy is the more complex and time-consuming procedure, which should only be performed by a (experienced) surgeon (144). Studies in the critical care environment suggest that, in the elective situation, cricothyroidotomy is simpler and (at worst) has a similar complication rate (145, 146). Cricothyroidotomy may be performed using three techniques: needle, wire-guided percutaneous, or surgical. Although needle cricothyroidotomy has long been advocated (147), recent work suggests surgical cricothyroidotomy is superior (148). When compared with a wire-guided technique, the surgical technique was both quicker (even when performed by non-surgeons) and produced more effective ventilation (149) in a mannequin. Previously, surgical cricothyroidotomy has been viewed as a temporary airway that should be converted to tracheostomy

within a few days. However, a surgical cricothyroidotomy can be used successfully as a definitive (medium-term) airway without any additional risk of complications (150, 151), whereas it would appear that the conversion from cricothyroidotomy to tracheostomy may be an unnecessary and high-risk procedure (152, 153).

## Extubation in the Patient with a Difficult Airway (Decannulation)

The patient with a difficult airway still poses a problem at extubation and, if reintubation is necessary, it may be even more difficult than the original procedure. Between 4% and 12% of surgical intensive care unit patients require reintubation (154) and may be hypoxic, distressed, and uncooperative at the time of the procedure. Such patients often have multiple risk factors for difficult intubation (71) as well as airway edema and the presence of dried blood and secretions. Reestablishing the airway in such patients is challenging. Before the extubation of any critical care patient, there should be a strategy that includes a plan for reintubation.

Airway exchange catheters (AEC), which allow gas exchange either by jet ventilation or oxygen insufflation, may be useful in the "difficult extubation" (2, 155, 156). The AEC is placed through the ETT, ensuring that the distal end remains proximal to the carina. The ETT can then be removed after a successful leak test and the AEC may remain *in situ* until the situation is judged to be stable (71).

## Tube Displacement in the Critical Care Unit

*Tracheal Tube.* ETT displacement in the intensive care unit is a life-threatening emergency that may result in significant morbidity (157). Although sometimes viewed as unavoidable, often there are preventable factors involved (158–160). Changes in patient posture or head position cause significant movement of the tube within the trachea (161, 162). The frequency of tube displacement can be reduced by good medical and nursing practice (163), attention to the spatial arrangements around the bed, achieving appropriate sedation levels, and ensuring appropriate intensive care unit nurse staffing (164, 165). The management of ETT displacement should include consideration that the patient may no longer

need an ETT (160). If replacement is required, one must prepare for a potentially difficult reintubation.

*Tracheostomy Tube.* Adverse events associated with tracheostomy tubes are quite common (160, 166). Tube displacement from the tracheal lumen may be impossible to detect on external examination but is suggested by difficulty with breathing, ventilation, or tracheal suctioning and the presence of a pneumothorax, pneumomediastinum, or surgical emphysema. If required, tube position and patency may be assessed by passing a fiberoptic scope through the lumen to visualize trachea and carina. Assessing tracheostomy tube position on chest x-ray is of no value.

If displacement occurs before a well-defined track between skin and trachea is formed (4–5 days), it may result in a life-threatening event. Displacement of a percutaneous tracheostomy tube may be problematic because the external opening of the track may not easily admit a new tube of the same size. The option to remove the tube (decannulate the patient) should be considered and if pursued, the tracheostomy opening should be dressed to make it as "airtight" as possible, thus facilitating effective coughing. If the patient needs a tube, and replacing the tracheostomy is not possible, then oral reintubation should be performed after which the tracheostomy should be dressed. A new tracheostomy procedure can be planned when appropriate. With a more mature tracheostomy (more than 5 days old), replacement of a displaced tube may be quite simple because the track between skin and the trachea is well formed (167).

## Summary

Critical care patients exhibit airway difficulties, which include all the scenarios found in anesthesia but in an environment and context that may be less favorable. The difficult airway frequently needs to be maintained over a prolonged period and the process of decannulation is potentially life-threatening. All critical care physicians need to be familiar with difficult airway algorithms and have the skills to use the necessary airway adjuncts. It is important that other critical care staff have the ability to provide support during difficult airway maneuvers. We should view all critical care airway problems as potentially difficult and plan accordingly.

## REFERENCES

- Practice guidelines for management of the difficult airway: An updated report by the American Society of Anesthesiologists Task Force on Management of the Difficult Airway. *Anesthesiology* 2003; 98:1269–1277
- Benumof JL: Management of the difficult adult airway. With special emphasis on awake tracheal intubation. *Anesthesiology* 1991; 75:1087–1110
- Rashkin MC, Davis T: Acute complications of endotracheal intubation. *Chest* 1986; 89: 165–167
- Caplan RA, Posner KL, Ward RJ, et al: Adverse respiratory events in anaesthesia: a closed claims analysis. *Anesthesiology* 1990; 72:828–833
- Rose DK, Cohen MM: The airway: Problems and predictions in 18,500 patients. *Can J Anaesth* 1994; 41:372–383
- Peterson GN, Domino KB, Caplan RA, et al: Management of the difficult airway: A closed claims analysis. *Anesthesiology* 2005; 103:33–39
- Burkle CM, Walsh MT, Harrison BA, et al: Airway management after failure to intubate by direct laryngoscopy: Outcomes in a large teaching hospital. *Can J Anaesth* 2005; 52:634–640
- Domino KB, Posner KL, Caplan RA, et al: Airway injury during anesthesia: a closed claims analysis. *Anesthesiology* 1999; 91: 1703–1711
- Needham DM, Thompson DA, Holzmüller CG, et al: A system factors analysis of airway events from the Intensive Care Unit Safety Reporting System (ICUSRS). *Crit Care Med* 2004; 32:2227–2233
- Beckmann U, Baldwin I, Hart GK, et al: The Australian Incident Monitoring Study in Intensive Care: AIMS-ICU. An analysis of the first year of reporting. *Anaesth Intensive Care* 1996; 24:320–329
- Beckmann U, Baldwin I, Durie M, et al: Problems associated with nursing staff shortage: An analysis of the first 3600 incident reports submitted to the Australian Incident Monitoring Study (AIMS-ICU). *Anaesth Intensive Care* 1998; 26:396–400
- Langeron O, Masso E, Huraux C, et al: Prediction of difficult mask ventilation. *Anesthesiology* 2000; 92:1229–1236
- Yildiz TS, Solak M, Toker K: The incidence and risk factors of difficult mask ventilation. *J Anaesth* 2005; 19:7–11
- Kheterpal S, Han R, Tremper KK, et al: Incidence and predictors of difficult and impossible mask ventilation. *Anesthesiology* 2006; 105:885–891
- Crosby ET, Cooper RM, Douglas MJ, et al: The unanticipated difficult airway with recommendations for management. *Can J Anaesth* 1998; 45:757–776
- Samsoon GLT, Young JRB: Difficult tracheal intubation: A retrospective study. *Anaesthesia* 1987; 42:487
- Cormac RS, Lehane J: Difficult tracheal intubation in obstetrics. *Anaesthesia* 1984; 39:1105–1111
- Calder I, Calder J, Crockard HA: Difficult direct laryngoscopy in patients with cervical spine disease. *Anaesthesia* 1995; 50: 756–763
- Ayuso MA, Sala X, Luis M, et al: Predicting difficult orotracheal intubation in pharyngo-laryngeal disease: Preliminary results of a composite index. *Can J Anaesth* 2003; 50:81–85
- Yentis SM, Lee DJ: Evaluation of an improved scoring system for the grading of direct laryngoscopy. *Anaesthesia* 1998; 53: 1041–1044
- Levitan RM, Ochroch EA, Kush S, et al: Assessment of airway visualization: validation of the percentage of glottic opening (POGO) scale. *Acad Emerg Med* 1998; 5:919–923
- Adnet F, Borron SW, Racine SX, et al: The intubation difficulty scale (IDS): Proposal and evaluation of a new score characterizing the complexity of endotracheal intubation. *Anesthesiology* 1997; 87:1290–1297
- Adnet F, Racine SX, Borron SW, et al: A survey of tracheal intubation difficulty in the operating room: A prospective observational study. *Acta Anaesthesiol Scand* 2001; 45:327–332
- Lavery GG, McCloskey B: Airway management. In: Patient Centred Acute Care Training (PACT). Roessler M, Fluit L, Ramsay G (Eds). Brussels: European Society of Intensive Care Medicine, 2003, pp 1–27
- Castello DA, Smith HS, Lumb PD: Conventional airway access. In: Textbook of Critical Care (TCC), Fourth Edition. Grenvik A, Ayres SM, Holbrook PR, et al (Eds). Philadelphia, WB Saunders, 1999, pp 1232–1246
- Yentis SM: Predicting difficult intubation—worthwhile exercise or pointless ritual? *Anaesthesia* 2002; 57:105–109
- Mallampati SR, Gatt SP, Gugino LD, et al: A clinical sign to predict difficult tracheal intubation: A prospective study. *Can Anaesth Soc J* 1985; 32:429
- Cattano D, Panicucci E, Paolicchi A, et al: Risk factors assessment of the difficult airway: An Italian survey of 1956 patients. *Anesth Analg* 2004; 99:1774–1779
- Farmery AD: Sternomental distance as predictor of difficult laryngoscopy. *Br J Anaesth* 1997; 78:626–627
- Ezri T, Weisenberg M, Khazin V, et al: Difficult laryngoscopy: Incidence and predictors in patients undergoing coronary artery bypass surgery versus general surgery patients. *J Cardiothorac Vasc Anesth* 2003; 17:321–324
- Ezri T, Medalion B, Weisenberg M, et al: Increased body mass index per se is not a predictor of difficult laryngoscopy. *Can J Anaesth* 2003; 50:179–183
- Randell T: Prediction of difficult intubation. *Acta Anaesthesiol Scand* 1996; 40: 1016–1023
- Savva D: Prediction of difficult tracheal intubation. *Br J Anaesth* 1994; 73:149–153
- El-Ganzouri AR, McCarthy RJ, Tuman KJ, et al: Preoperative airway assessment predictive value of a multivariate risk index. *Anesth Analg* 1996; 82:1197–2004
- Voyagis GS, Kyriakos KP: The effect of goiter on endotracheal intubation. *Anesth Analg* 1997; 84:611–612
- Wakeling HG, Ody A, Ball A: Large goitre causing difficult intubation and failure to intubate using the intubating laryngeal mask airway: Lessons for next time. *Br J Anaesth* 1998; 81:979–981
- Shaw IC, Welch EA, Harrison BJ, et al: Complete airway obstruction during awake fiberoptic intubation. *Anaesthesia* 1997; 52: 582–585
- Amathieu R, Smail N, Catoire J, et al: Difficult intubation in thyroid surgery: Myth or reality? *Anesth Analg* 2006; 103: 965–968
- Bouaggad A, Nejmi SE, Bouderkha MA, et al: Prediction of difficult tracheal intubation in thyroid surgery. *Anesth Analg* 2004; 99: 603–606
- Saha AR, Burnett C, Alfonso A, et al: Goitres and airway problems. *Am J Surg* 1989; 158: 378–380
- Schmitt H, Buchfelder M, Radespiel-Tröger M, et al: Difficult intubation in acromegalic patients: Incidence and predictability. *Anesthesiology* 2000; 93:110–114
- Rosenstock C, Kristensen MS: Decreased tongue mobility—an explanation for difficult endotracheal intubation? *Acta Anaesthesiol Scand* 2005; 49:92–94
- Wilson ME, Spiegelhalter D, Robertson JA, et al: Predicting difficult intubation. *Br J Anaesth* 1988; 61:211–216
- Oates JDL, Macleod AD, Oates PD, et al: Comparison of two methods for predicting difficult intubation. *Br J Anaesth* 1991; 66: 305–309
- Gupta S, Pareek S, Dulara SC: Comparison of two methods for predicting difficult intubation in obstetric patients. *Middle East J Anaesthesiol* 2003; 17:275–285
- Merah NA, Wong DT, Foulkes-Crabbe DJ, et al: Modified Mallampati test, thyromental distance and inter-incisor gap are the best predictors of difficult laryngoscopy in West Africans. *Can J Anaesth* 2005; 52:291–296
- Arné J, Descoins P, Fusciardi J, et al: Preoperative assessment for difficult intubation in general and ENT surgery: Predictive value of a clinical multivariate risk index. *Br J Anaesth* 1998; 80:140–146
- Rose DK, Cohen MM: The airway: Problems and predictions in 18,500 patients. *Can J Anaesth* 1994; 41:372–383
- Juvin P, Lavaut E, Dupont H, et al: Difficult tracheal intubation is more common in obese than in lean patients. *Anesth Analg* 2003; 97:595–600
- Brodsky JB, Lemmens HJ, Brock-Utne JG, et al: Morbid obesity and tracheal intubation. *Anesth Analg* 2002; 94:732–736



51. Komatsu R, Sengupta P, Wadhwa A, et al: Ultrasound quantification of anterior soft tissue thickness fails to predict difficult laryngoscopy in obese patients. *Anaesth Intensive Care* 2007; 35:32–37
52. Rosenblatt WH: Preoperative planning of airway management in critical care patients. *Crit Care Med* 2004; 32:S186–192
53. Awad Z, Pothier DD: Management of surgical airway emergencies by junior ENT staff: a telephone survey. *J Laryngol Otol* 2007; 121:57–60
54. Rosenstock C, Ostergaard D, Kristensen MS, et al: Residents lack knowledge and practical skills in handling the difficult airway. *Acta Anaesthesiol Scand* 2004; 48: 1014–1018
55. Schwid HA, Rooke GA, Carline J, et al: Evaluation of anesthesia residents using mannequin-based simulation: A multiinstitutional study. *Anesthesiology* 2002; 97: 1434–1444
56. Sagarin MJ, Barton ED, Chng YM, et al: Airway management by US and Canadian emergency medicine residents: A multicenter analysis of more than 6,000 endotracheal intubation attempts. *Ann Emerg Med* 2005; 46:328–336
57. Kluger MT, Short TG: Aspiration during anaesthesia: A review of 133 cases from the Australian Anaesthetic Incident Monitoring Study (AIMS). *Anaesthesia* 1999; 54:19–26
58. Mayo PH, Hackney JE, Mueck JT, et al: Achieving house staff competence in emergency airway management: results of a teaching program using a computerized patient simulator. *Crit Care Med* 2004; 32: 2422–2427
59. Vickers MD: Anaesthetic team and the role of nurses—European perspective. *Best Pract Res Clin Anaesthesiol* 2002; 16: 409–421
60. James MR, Milsom PL: Problems encountered when administering general anaesthetics in accident and emergency departments. *Arch Emerg Med* 1988; 5:151–155
61. Kluger MT, Bukofzer M, Bullock M, et al: Anaesthetic assistants: Their role in the development and resolution of anaesthetic incidents. *Anaesth Intensive Care* 1999; 27: 269–274
62. Kluger MT, Bullock MF: Recovery room incidents: A review of 419 reports from the Anaesthetic Incident Monitoring Study (AIMS). *Anaesthesia* 2002; 57:1060–1066
63. Robbertze R, Posner KL, Domino KB: Closed claims review of anesthesia for procedures outside the operating room. *Curr Opin Anaesthesiol* 2006; 19:436–442
64. Wang HE, Seitz SR, Hostler D, et al: Defining the learning curve for paramedic student endotracheal intubation. *Prehosp Emerg Care* 2005; 2:156–162
65. Wang HE, Kupas DF, Paris PM, et al: Multivariate predictors of failed prehospital endotracheal intubation. *Acad Emerg Med* 2003; 10:717–724
66. Krisanda TJ, Eitel DR, Hess D, et al: An analysis of invasive airway management in a suburban emergency medical services system. *Prehosp Disaster Med* 1992; 7:121–126
67. Wang HE, Sweeney TA, O'Connor RE, et al: Failed prehospital intubations: An analysis of emergency department courses and outcomes. *Prehosp Emerg Care* 2001; 5:134–141
68. Schwartz DE, Matthay MA, Cohen NH: Death and other complications of emergency airway management in critically ill adults. A prospective investigation of 297 tracheal intubations. *Anesthesiology* 1995; 82:367–376
69. Brimacombe J, Keller C, Kunzel KH, et al: Cervical spine motion during airway management: A cinefluoroscopic study of the posteriorly destabilized third cervical vertebrae in human cadavers. *Anesth Analg* 2000; 91:1274–1278
70. Waltl B, Melischek M, Schuschnig C, et al: Tracheal intubation and cervical spine excursion: Direct laryngoscopy vs. intubating laryngeal mask. *Anaesthesia* 2001; 56: 221–226
71. Loudermilk EP, Hartmannsgruber M, Stoltzfus DP, et al: A prospective study of the safety of tracheal extubation using a pediatric airway exchange catheter for patients with a known difficult airway. *Chest* 1997; 111:1660–1665
72. Sims CA, Berger DL: Airway risk in hospitalized trauma patients with cervical injuries requiring halo fixation. *Ann Surg* 2002; 235:280–284
73. Mort TC: Preoxygenation in critically ill patients requiring emergency tracheal intubation. *Crit Care Med* 2005; 33:2672–2675
74. Janssens M, Hartstein G: Management of difficult intubation. *Eur J Anaesthesiol* 2001; 18:3–12
75. Henderson JJ, Popat MT, Latto IP, et al: Difficult Airway Society guidelines for management of the unanticipated difficult intubation. *Anaesthesia* 2004; 59:675–694
76. Benumof JL: Laryngeal mask airway and the ASA difficult airway algorithm. *Anesthesiology* 1996; 84:686–699
77. Heidegger T, Gerig HJ: Algorithms for management of the difficult airway. *Curr Opin Anaesthesiol* 2004; 17:483–484
78. Morris IR: Continuing medical education: Fiberoptic intubation. *Can J Anesth* 1994; 41:996–1008
79. Jolliet P, Chevolet JC: Bronchoscopy in the intensive care unit. *Intensive Care Med* 1992; 18:160–169
80. Ovassapian A: Fiberoptic Endoscopy and the Difficult Airway. Second Edition. Philadelphia, Lippincott-Raven, 1996
81. Popat M: *Practical Fiberoptic Intubation*. Oxford, Butterworth-Heinemann, 2001
82. Benumof JL: *Airway Management: Principles and Practice*. St. Louis, Mosby-Year Book, 1996
83. Koerner IP, Brambrink AM: Fiberoptic techniques. *Best Pract Res Clin Anaesthesiol* 2005; 19:611–621
84. Reasoner DK, Warner DS, Todd MM, et al: A comparison of anesthetic techniques for awake intubation in neurosurgical patients. *J Neurosurg Anesthesiol* 1995; 7:94–99
85. Graham DR, Hay JG, Clague J, et al: Comparison of three different methods used to achieve local anaesthesia for fiberoptic bronchoscopy. *Chest* 1992; 102:704–707
86. Gupta B, McDonald JS, Brooks JH, et al: Oral fiberoptic intubation over a retrograde guidewire. *Anesth Analg* 1989; 68:517–519
87. Finucane BT, Santora AH: Fiberoptic intubation in airway management. *In: Principles of Airway Management*. Second Edition. Finucane BT, Santora AH (Eds). St. Louis, Mosby Year-Book, 1996, p 102
88. Bagade A, Jefferson O, Ball DR: Retrograde tracheal intubation. *Anaesthesia* 2006; 61: 1223–1223
89. Kabrhel C, Thomsen TW, Setnik GS, et al: Videos in clinical medicine. Orotracheal intubation. *N Engl J Med* 2007; 356:e15
90. Knill RL: Difficult laryngoscopy made easy with a 'BURP.' *Can J Anaesth* 1993; 40: 279–282
91. Latto IP, Stacey M, Mecklenburgh J, et al: Survey of the use of the gum elastic bougie in clinical practice. *Anaesthesia* 2002; 57: 379–384
92. Tamura M, Ishikawa T, Kato R, et al: Mandibular advancement improves the laryngeal view during direct laryngoscopy performed by inexperienced physicians. *Anesthesiology* 2004; 100:598–601
93. Levitan RM, Kinkle WC, Levin WJ, et al: Laryngeal view during laryngoscopy: A randomized trial comparing cricoid pressure, backward-upward-rightward pressure, and bimanual laryngoscopy. *Ann Emerg Med* 2006; 47:548–555
94. Yentis SM: The effects of single-handed and bimanual cricoid pressure on the view at laryngoscopy. *Anaesthesia* 1997; 52: 332–335
95. Snider DD, Clarke D, Finucane BT: The 'BURP' maneuver worsens the glottic view when applied in combination with cricoid pressure. *Can J Anaesth* 2005; 52:100–104
96. Levitan RM, Mickler T, Hollander JE: Bimanual laryngoscopy: A videographic study of external laryngeal manipulation by novice intubators. *Ann Emerg Med* 2002; 40: 30–37
97. Finucane BT, Santora AH: Difficult intubation. *In: Principles of Airway Management*. Second Edition. Finucane BT, Santora AH (Eds). St. Louis, Mosby Year-Book, 1996, p 191
98. Bokhari A, Benham SW, Popat MT: Management of unanticipated difficult intubation: A survey of current practice in the Oxford region. *Eur J Anaesthesiol* 2004; 21: 123–127
99. Gataure PS, Vaughan RS, Latto IP: Simulated difficult intubation. Comparison of the gum elastic bougie and the stylet. *Anaesthesia* 1996; 51:935–938
100. Benumof JL: Comparison of the gum elastic

- bougie and the stylet. *Anaesthesia* 1997; 52:385–386
101. MacQuarrie K, Hung OR, Law JA: Tracheal intubation using Bullard laryngoscope for patients with a simulated difficult airway. *Can J Anaesth* 1999; 46:760–765
  102. Yardeni IZ, Gefen A, Smolyarenko V, et al: Design evaluation of commonly used rigid and levering laryngoscope blades. *Acta Anaesthesiol Scand* 2002; 46:1003–1009
  103. McIntyre JW: Laryngoscope design and the difficult adult tracheal intubation. *Can J Anaesth* 1989; 36:94–98
  104. Sethuraman D, Darshane S, Guha A, et al: A randomised, crossover study of the Dorges, McCoy and Macintosh laryngoscope blades in a simulated difficult intubation scenario. *Anaesthesia* 2006; 61:482–487
  105. Cook TM, Tuckey JP: A comparison between the Macintosh and the McCoy laryngoscope blades. *Anaesthesia* 1996; 51:977–980
  106. Chisholm DG, Calder I: Experience with the McCoy laryngoscope in difficult laryngoscopy. *Anaesthesia* 1997; 52:906–908
  107. Hung OR, Stewart RD: Lightwand intubation: A new lightwand device. *Can J Anaesth* 1995; 42:820–825
  108. Mehta S: Transtracheal illumination for optimal tracheal tube placement. A clinical study. *Anaesthesia* 1989; 44:970–972
  109. Hung OR, Pytka S, Morris I: Clinical trial of a new lightwand device (Trachlight) to intubate the trachea. *Anesthesiology* 1995; 83:509–514
  110. Wong DT, Lai K, Chung FF, et al: Cannot intubate-cannot ventilate and difficult intubation strategies: Results of a Canadian national survey. *Anesth Analg* 2005; 100:1439–1446
  111. Agrò F, Brimacombe J, Carassiti M, et al: Use of a lighted stylet for intubation via the laryngeal mask airway. *Can J Anaesth* 1998; 45:556–560
  112. Lupien AE, Taylor C: Hybrid intubation technique for the management of a difficult airway: A case report. *AANA J* 1995; 63:50–52
  113. Randell T, Valli H, Hakala P: Comparison between the Ovassapian intubating airway and the Berman intubating airway in fiberoptic intubation. *Eur J Anaesthesiol* 1997; 14:380–384
  114. Benjamin FJ, Boon D, French RA: An evaluation of the GlideScope, a new video laryngoscope for difficult airways: A manikin study. *Eur J Anaesthesiol* 2006; 23:517–521
  115. Cook TM, Hommers C: New airways for resuscitation. *Resuscitation* 2006; 69:371–387
  116. Brain AI: The development of the laryngeal mask—a brief history of the invention, early clinical studies and experimental work from which the laryngeal mask evolved. *Eur J Anaesthesiol Suppl* 1991; 4:5–17
  117. Maltby JR, Loken RG, Watson NC: The laryngeal mask airway: Clinical appraisal in 250 patients. *Can J Anaesth* 1990; 37:509–513
  118. Pennant JH, White PF: The laryngeal mask airway. Its uses in anesthesiology. *Anesthesiology* 1993; 79:144–163
  119. Ramachandran K, Kannan S: Laryngeal mask airway and the difficult airway. *Curr Opin Anaesthesiol* 2004; 17:491–493
  120. Ezri T, Szmuk P, Warters RD, et al: Difficult airway management practice patterns among anesthesiologists practicing in the United States: Have we made any progress? *J Clin Anesth* 2003; 15:418–422
  121. Parmet JL, Colonna-Romano P, Horrow JC, et al: The laryngeal mask airway reliably provides rescue ventilation in cases of unanticipated difficult tracheal intubation along with difficult mask ventilation. *Anesth Analg* 1998; 87:661–665
  122. Davies PR, Tighe SQ, Greenslade GL, et al: Laryngeal mask airway and tracheal tube insertion by unskilled personnel. *Lancet* 1990; 336:997–999
  123. Reinhardt DJ, Simmons G: Comparison of placement of the laryngeal mask airway with endotracheal tube by paramedics and respiratory therapists. *Ann Emerg Med* 1994; 24:260–263
  124. Stone BJ, Chantler PJ, Baskett PJ: The incidence of regurgitation during cardiopulmonary resuscitation: A comparison between the bag mask valve and laryngeal mask airway. *Resuscitation* 1998; 38:3–6
  125. Devitt JH, Wenstone R, Noel AG, et al: The laryngeal mask airway and positive pressure ventilation. *Anesthesiology* 1994; 80:550–555
  126. Brain AI, Verghese C, Addy EV, et al: The intubating laryngeal mask. II: A preliminary clinical report of a new means of intubating the trachea. *Br J Anaesth* 1997; 79:699–703
  127. Joo HS, Kapoor S, Rose DK, et al: The intubating laryngeal mask airway after induction of general anesthesia versus awake fiberoptic intubation in patients with difficult airways. *Anesth Analg* 2001; 92:1342–1346
  128. Combes X, Sauvats S, Leroux B, et al: Intubating laryngeal mask airway in morbidly obese and lean patients: A comparative study. *Anesthesiology* 2005; 102:1106–1109
  129. Combes X, Le Roux B, Suen P, et al: Unanticipated difficult airway in anesthetized patients: Prospective validation of a management algorithm. *Anesthesiology* 2004; 100:1146–1150
  130. Choyce MS, Avidan C, Patel A, et al: Comparison of laryngeal mask and intubating laryngeal mask insertion by the naive intubator. *Br J Anaesth* 2000; 84:103–105
  131. Kihara S, Watanabe S, Brimacombe J, et al: Segmental cervical spine movement with the intubating laryngeal mask during manual in-line stabilization in patients with cervical pathology undergoing cervical spine surgery. *Anesth Analg* 2000; 91:195–200
  132. Cook TM, Lee G, Nolan J: The ProSeal™ Laryngeal mask airway: A review of the literature. *Can J Anaesth* 2005; 52:739–760
  133. Rabitsch W, Schellongowski P, Staudinger T, et al: Comparison of a conventional tracheal airway with the Combitube in an urban emergency medical services system run by physicians. *Resuscitation* 2003; 57:27–32
  134. Mort TC: Laryngeal mask airway and bougie intubation failures: the Combitube as a secondary rescue device for in-hospital emergency airway management. *Anesth Analg* 2006; 103:1264–1266
  135. Rumball CJ, MacDonald D: The PTL, Combitube, laryngeal mask, and oral airway: A randomized prehospital comparative study of ventilatory device effectiveness and cost-effectiveness in 470 cases of cardiorespiratory arrest. *Prehosp Emerg Care* 1997; 1:1–10
  136. Mulcahy AJ, Yentis SM: Management of the unexpected difficult airway. *Anaesthesia* 2005; 60:1147–1148
  137. Schwartz DE, Matthay MA, Cohen NH: Death and other complications of emergency airway management in critically ill adults. A prospective investigation of 297 tracheal intubations. *Anesthesiology* 1995; 82:367–376
  138. Birmingham PK, Cheney FW, Ward RJ: Esophageal intubation: A review of detection techniques. *Anesth Analg* 1986; 65:886–891
  139. Erasmus PD: The use of end-tidal carbon dioxide monitoring to confirm endotracheal tube placement in adult and paediatric intensive care units in Australia and New Zealand. *Anaesth Intensive Care* 2004; 32:672–675
  140. Linko K, Paloheimo M, Tammisto T: Capnography for detection of accidental oesophageal intubation. *Acta Anaesthesiol Scand* 1983; 27:199–202
  141. Sum Ping ST, Mehta MP, Symreng T: Reliability of capnography in identifying esophageal intubation with carbonated beverage or antacid in the stomach. *Anesth Analg* 1991; 73:333–337
  142. Falk JL, Rackow EC, Weil MH: End-tidal carbon dioxide concentration during cardiopulmonary resuscitation. *N Engl J Med* 1988; 318:607
  143. Schwartz DE, Lieberman JA, Cohen NH: Women are at greater risk than men for malpositioning of the endotracheal tube after emergent intubation. *Crit Care Med* 1994; 22:1127–1131
  144. Finucane BT, Santora AH: Surgical approaches to airway management. In: Principles of Airway Management. Second Edition. Finucane BT, Santora AH (Eds). St. Louis, Mosby Year-Book, 1996, pp 251–284
  145. Rehm CG, Wanek SM, Gagnon EB, et al: Cricothyroidotomy for elective airway management in critically ill trauma patients with technically challenging neck anatomy. *Crit Care* 2002; 6:531–535
  146. Francois B, Clavel M, Desachy A, et al: Complications of tracheostomy performed in the ICU: Subthyroid tracheostomy vs surgical cricothyroidotomy. *Chest* 2003; 123:151–158

147. Smith RB, Schaer WB, Pfaeffle H: Percutaneous transtracheal ventilation for anaesthesia and resuscitation: A review and report of complications. *Can Anaesth Soc J* 1975; 22:607–612
148. Scrase I, Woollard M: Needle vs surgical cricothyroidotomy: A short cut to effective ventilation. *Anaesthesia* 2006; 61:921–923
149. Sulaiman L, Tighe SQ, Nelson RA: Surgical vs wire-guided cricothyroidotomy: A randomised crossover study of cuffed and uncuffed tracheal tube insertion. *Anaesthesia* 2006; 61:565–570
150. Brantigan CO, Grow JB: Cricothyroidotomy: Elective use in respiratory problems requiring tracheostomy. *Thorac Cardiovasc Surg* 1976; 71:72–81
151. Wright MJ, Greenberg DE, Hunt JP, et al: Surgical cricothyroidotomy in trauma patients. *South Med J* 2003; 96:465–467
152. DeLaurier GA, Hawkins ML, Treat RC, et al: Acute airway management. Role of cricothyroidotomy. *Am Surg* 1990; 56:12–15
153. Altman KW, Waltonen JD, Kern RC: Urgent surgical airway intervention: A 3 year county hospital experience. *Laryngoscope* 2005; 115:2101–2104
154. Demling RH, Read T, Lind LJ, et al: Incidence and morbidity of extubation failure in surgical intensive care patients. *Crit Care Med* 1988; 16:573–577
155. Bedger RC Jr, Chang JL: A jet-stylet endotracheal catheter for difficult intubation airway management. *Anesthesiology* 1987; 66:221–223
156. Cooper RM: The use of an endotracheal ventilation catheter in the management of difficult extubations. *Can J Anaesth* 1996; 43:90–93
157. Epstein SK, Nevins ML, Chung J: Effect of unplanned extubation on outcome of mechanical ventilation. *Am J Respir Crit Care Med* 2000; 161:1912–1916
158. Rothschild JM, Landrigan CP, Cronin JW, et al: The Critical Care Safety Study: The incidence and nature of adverse events and serious medical errors in intensive care. *Crit Care Med* 2005; 33:1694–1700
159. Beckmann U, Gillies DM: Factors associated with reintubation in intensive care: an analysis of causes and outcomes. *Chest* 2001; 120:538–542
160. Kapadia FN, Bajan KB, Raje KV: Airway accidents in intubated intensive care unit patients: An epidemiological study. *Crit Care Med* 2000; 28:659–664
161. Conrardy PA, Goodman LR, Lainge F, et al: Alteration of endotracheal tube position: Flexion and extension of the neck. *Crit Care Med* 1976; 4:7
162. Yap SJ, Morris RW, Pybus DA: Alterations in endotracheal tube position during general anaesthesia. *Anaesth Intensive Care* 1994; 22:586–588
163. Birkett KM, Southerland KA, Leslie GD: Reporting unplanned extubation. *Intensive Crit Care Nurs* 2005; 21:65–75
164. Morrison AL, Beckmann U, Durie M, et al: The effects of nursing staff inexperience (NSI) on the occurrence of adverse patient experiences in ICUs. *Aust Crit Care* 2001; 14:116–121
165. Chevron V, Menard JF, Richard JC, et al: Unplanned extubation: Risk factors of development and predictive criteria for reintubation. *Crit Care Med* 1998; 26:1049–1053
166. Kapadia FN, Bajan KB, Singh S, et al: Changing patterns of airway accidents in intubated ICU patients. *Intensive Care Med* 2001; 27:296–300
167. Hazard PB: Tracheostomy. In: Oxford Textbook of Critical Care. Webb AR, Shapiro MJ, Singer M, et al (Eds). Oxford, Oxford University Press, pp 1305–1308